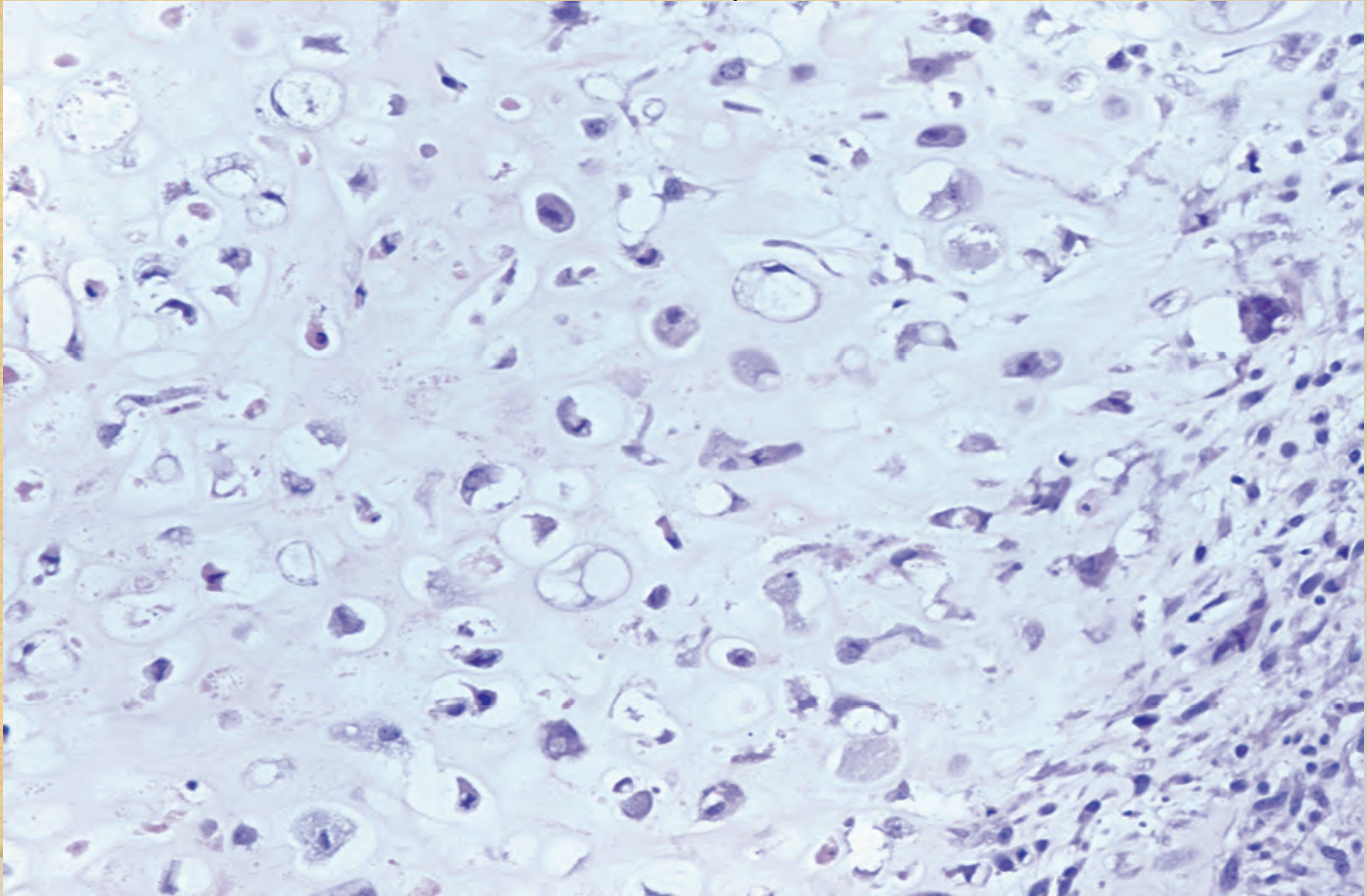


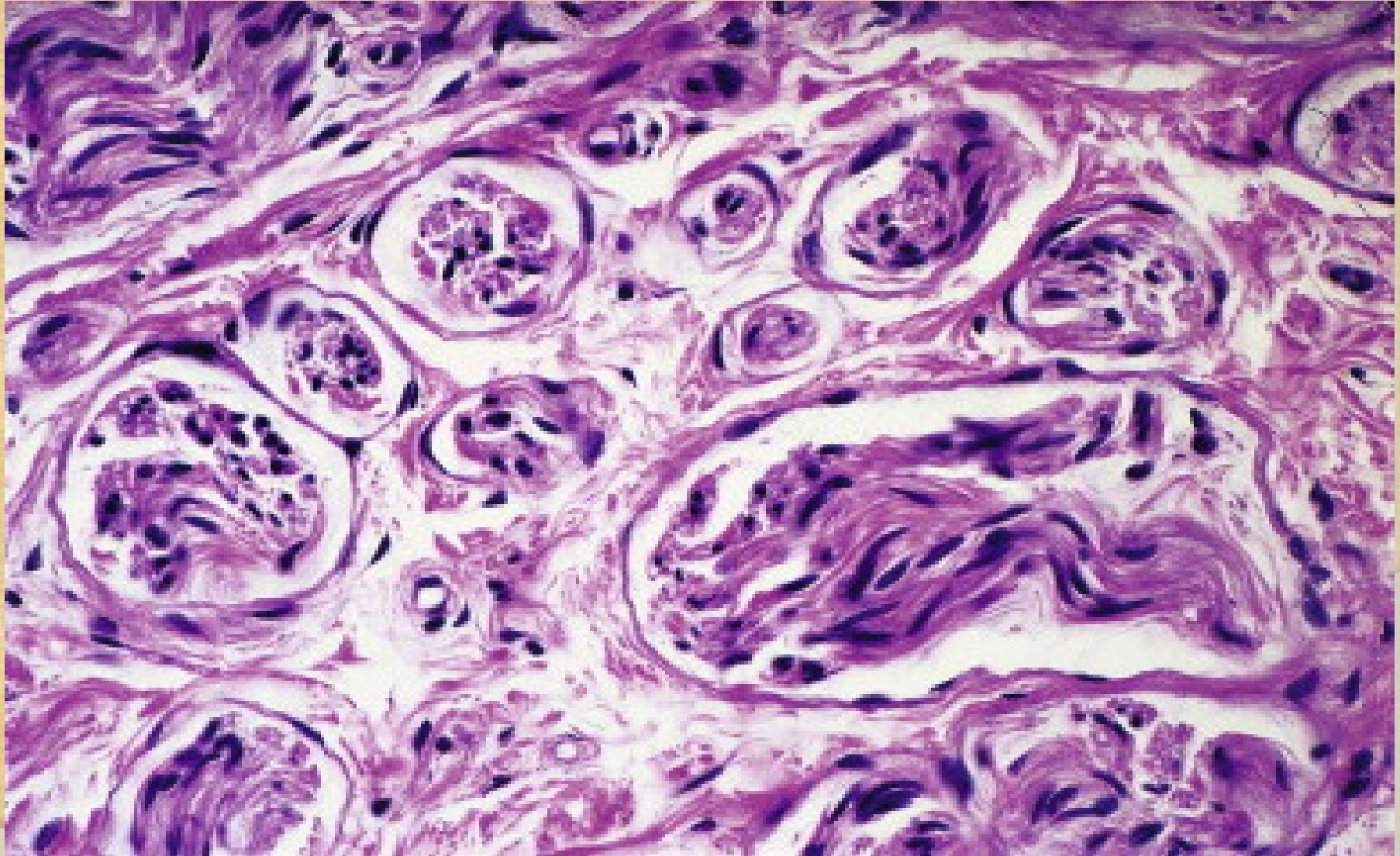
# Chondrosarcoma

Cartilage matrix resembles normal cartilage, but the chondrocytes are pleomorphic in size and shape.

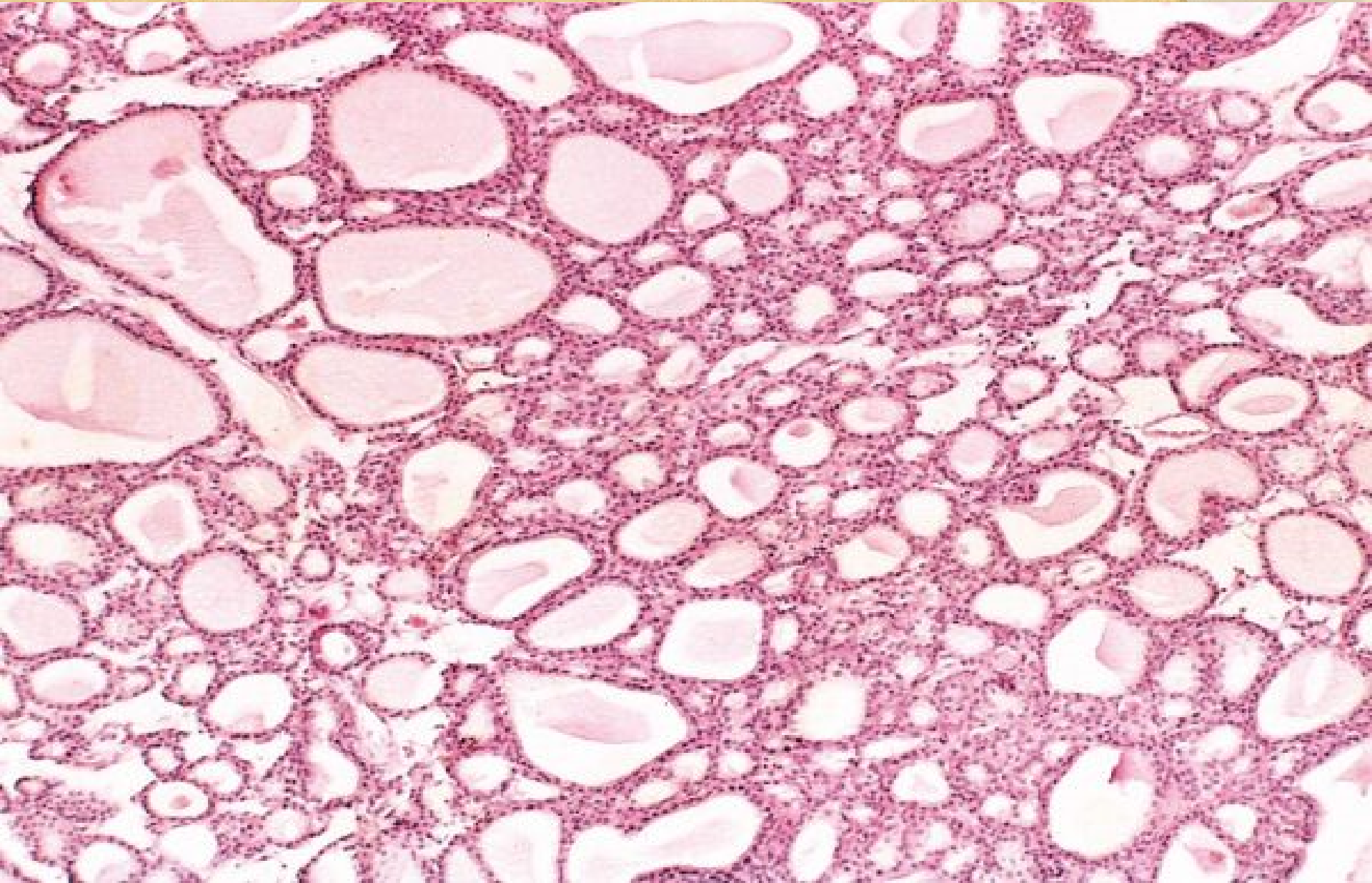


# Traumatic Neuroma

The haphazardly distributed nerve trunks are surrounded by fibrous tissue.



**Benign tumor: Adenoma) of the thyroid.** Note the normal-looking (well-differentiated), colloid-filled thyroid follicles.



**Adenocarcinoma of colon.** Note that the cancerous glands are irregular in shape and size and do not resemble the normal colonic glands. This tumor is considered differentiated because gland formation can be seen.

